



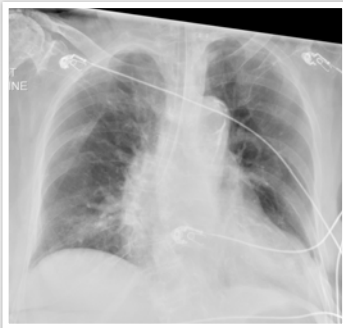Lines, tubes, and devices

Abnormal ETT positioning

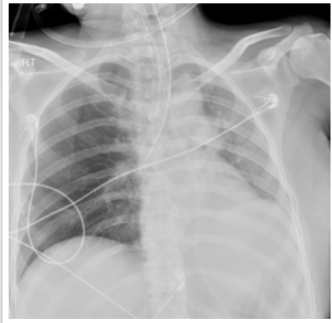
What will I gain from this video?

After watching this video, you will know how to identify aberrantly positioned ETT tubes.

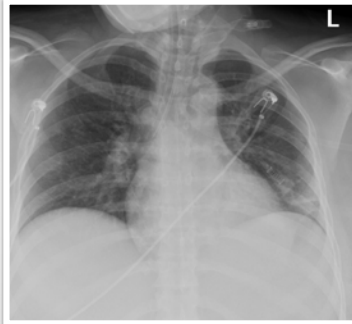
Case 1



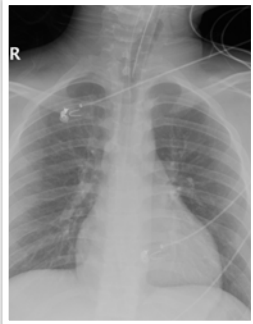
Case 2



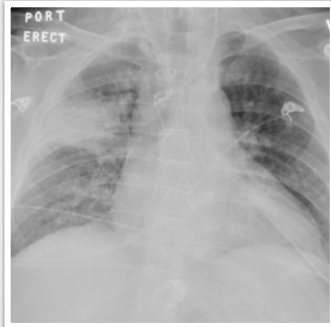
Case 3



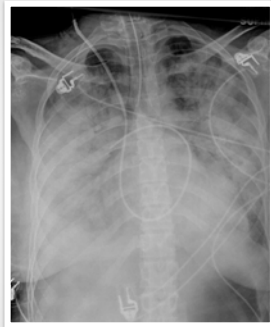Case 4



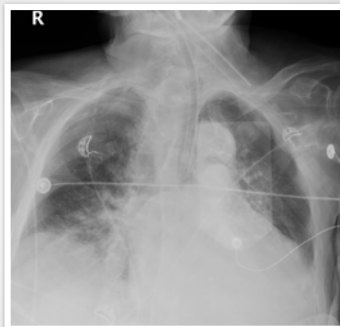
Case 5



Case 6



Case 7



Airway tubes can be positioned too high or too low.

Airway tubes can be positioned aberrantly.

Aberrant position within a bronchus can lead to collapse of the contralateral lung.

A post-intubation X-ray is necessary for position assessment.

